

A review of swine influenza diagnostics

Lani L. Vincent, DVM, MS

Swine influenza continues to be an important problem in swine herds, comprising 10% or more of swine respiratory disease cases submitted to midwest diagnostic laboratories. Although swine influenza is a disease of low mortality, it remains important both because of its high morbidity and subsequent economic considerations in hog herds, and because of human health considerations. Sporadic cases have been documented in which humans in close contact with infected hogs have also become infected.¹

With the recent media attention influenza has received, it is imperative that we do a good job of diagnosing influenza in swine, not only for the sake of swine herd health, but because of the human health risk. There is a real potential for new genetic variants to emerge, as swine can become infected with both avian and mammalian influenza, and therefore serve as “mixing vessels.” With flu season well underway, a review of swine influenza diagnostics seems in order.

Traditionally, clinical signs have been the primary way to diagnose swine flu. Typically, most of the herd becomes affected nearly simultaneously with anorexia, fever, and a sharp cough. In the absence of secondary invaders, recovery is near complete in 7–10 days.² This poses a problem for the diagnostician, because samples taken during the acute phase of the disease are most useful for diagnostic confirmation, and often the disease has run its course by the time samples are submitted or received. Additionally, there is evidence that the virus can circulate in a herd throughout the year, and remain subclinical.³ Disease may then only become apparent when other etiologic agents are introduced into the herd. Reproductive, farrowing, and neonatal problems have been reported and suspected to be related to infection with swine influenza, but evidence is lacking to provide a direct correlation.³

Gross lesions of swine influenza are mild interstitial pneumonia (lung partially fails to collapse) and usually firm, plum-colored areas generally found in the ventral portions of the cranial and middle lung lobes, although in severe cases a high percent of the lung may be involved.² Gross lesions can be impossible to distinguish from those of porcine reproductive and respiratory syndrome (PRRS) or mycoplasma.

Histopathology is useful because influenza typically causes airway epithelial cell necrosis.⁴ Overall, there is diffuse interstitial thickening with congestion, edema, necrosis or erosion of the bronchiolar epithelium, and often loose peribronchiolar lymphoid cuffing. Frequently, purulent exudate is present within airway lumina (Figure 1). Typical PRRS lesions include multifocal-coalescing interstitial thickening with

proliferation of type-2 pneumocytes. Microscopic mycoplasmal lesions are multifocal peribronchiolar lymphoid cuffing.

The microscopic lesions will usually be present in the tissues for several days after the virus can be demonstrated by other laboratory methods. The best tissue samples to submit to the diagnostic laboratory are those from acutely sick, sacrificed, or recently dead animals. Samples should be placed in 10% formalin immediately. Samples taken from ventral areas of the cranial and middle lung lobes are most likely to be affected, and therefore are usually the best areas from which to obtain samples.

Immunohistochemistry (IHC) is a valuable tool to specifically identify influenza in formalin-fixed tissue.^{5,6} This becomes particularly useful in cases in which fixed lung has been submitted, but fresh tissue has spent too long in transit and is too autolytic to be of value; or if influenza is suspected after the fresh tissues are no longer available. A monoclonal antibody directed at the nucleoprotein of influenza virus will specifically stain individual infected cells^{5,6} (Figure 2). Results can usually be obtained within 24 hours after receiving fixed tissue.

Isolating the virus is a definitive method of demonstrating the presence of influenza. This can be accomplished by either inoculation of embryonated chicken eggs or tissue cultures with lung homogenate prepared from affected lung tissue.⁷ Fresh, acutely affected tissue containing live virus is necessary, and the process usually will take at least 4 days.

Fluorescent antibody examination of fresh tissue is economical and useful, as same-day results are possible.⁷ Again, samples taken during the acute phase of the disease are necessary. False negatives will result if samples are taken too late during the disease process, if tissues are autolyzed, or if samples are not taken from affected areas of the lungs.

Serology is of some use, although its drawbacks are evident. Often “clean” herds will demonstrate an antibody titer in the absence of clinical signs or history of influenza in the herd. An antibody response to an acute infection lags behind demonstration of the virus by other methods. Serology has been useful in the past as a retrospective indicator of presence of influenza in a herd. For demonstration of a current infection, it is necessary to identify the presence of the virus or viral nucleic acid.

Two ELISA kits are currently available and have been evaluated on both nasal swabs and lung homogenate from experimentally infected pigs.⁸ One is a microwell plate system (Bartels PRIMA System™ Influenza A Enzyme Immunoassay, Baxter Diagnostics, Inc., Deerfield, Illinois) and the other is a membrane ELISA kit (Directigen™ Flu-A Becton Dickinson Microbiology Systems, Cockeysville, Maryland) designed to perform individual tests (Figure 3). Both kits were originally created to diagnose human influenza, but adapt well to veterinary use since it is type-A influenza that is important in both human and veterinary

LLV: Animal Disease Research and Diagnostic Laboratory; Veterinary Science Department; South Dakota State University, Brookings, South Dakota, 57007

This diagnostic note has been peer-reviewed.

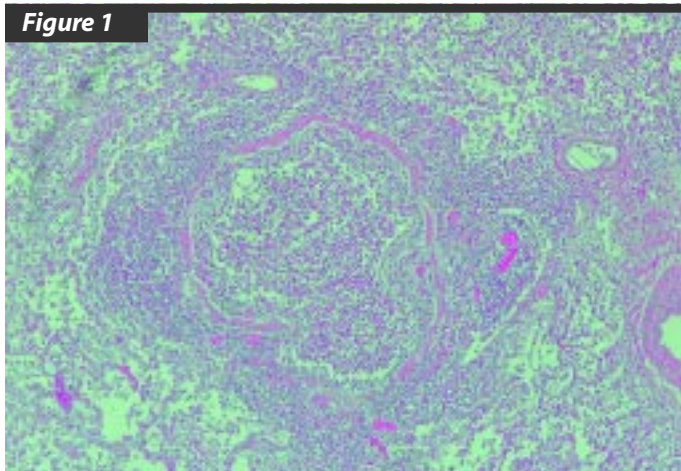


Figure 1

Microscopic lesions of swine influenza

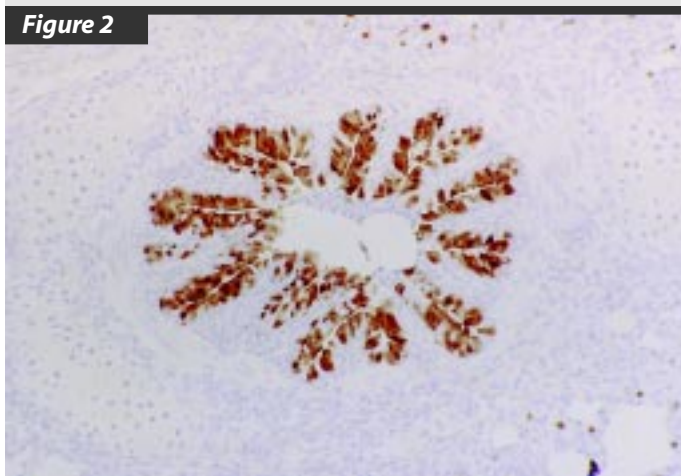


Figure 2

Immunohistochemistry showing positively stained cells lining bronchiol

medicine. As with IHC, both ELISA kits use a monoclonal antibody directed at the influenza virus nucleoprotein. The microwell system is more suited to diagnostic laboratory use, since it is only economically feasible to run multiple samples at once. The cost per test is reasonable if multiple samples are run, and results will be available in a few hours. However, the membrane kit has potential for use in veterinary clinics, and the entire procedure can be completed in about 15 minutes. Current problems include test kit availability, cost of individual tests, and a high number of “invalid” tests requiring that samples be diluted and rerun.⁶ In experimental conditions, virus can be identified in nasal swabs through day 5 postinoculation. A table is included that compares identification of SIV in lung tissue by ELISA kits, IHC, FA, or virus isolation in cell culture to identification by egg inoculation (Table 1).⁸

In conclusion, the herd situation should dictate the appropriate diagnostic test. The field veterinarian is responsible for knowing what tests are available in order to make an educated request to the diagnostic laboratory, for submitting appropriate samples, and for providing an adequate history. As always, best results will be obtained when samples are taken from acutely affected, untreated animals, and proper samples are collected and submitted to arrive in an unautolyzed condition.



Figure 3

Membrane EIA
courtesy, TM Chambers

Table 1

Comparison of egg inoculation with other assays for detecting SIV in lungs⁸

Assay	n=	% agreement	% egg - / EIA* +	% egg + / EIA -
Membrane EIA	35	85.7	2.8	11.4
Microwell EIA	33 [†]	54.5	15.2 [‡]	30.0
IHC	35	68.6	8.6 [§]	22.8
FA	35	80	11.4	8.6
Virus isolation	35	80	2.8	14.3

* EIA - enzyme immunoassay
[†] 35 samples evaluated—two samples indeterminate on initial and repeat tests
[‡] 4 samples negative by all assays except microwell EIA
[§] 1 sample negative by all assays except IHC
^{||} 2 samples negative by all assays except FA

References

1. Wentworth DE, Thompson BL, Xu X, Regnery HL, Cooley AJ, McGregor MW, Cox NJ, Hinshaw VS. An influenza A (H1N1) virus, closely related to swine influenza virus, responsible for a fatal case of human influenza. *J Virol.* 1994; 2051–2058.
2. Easterday BC, Hinshaw VS. Swine Influenza. in Leman AD, et al., eds. *Diseases of Swine*, 7th ed., Iowa State University Press, Ames, Iowa. 1992; 349–357.
3. Hinshaw VS, Easterday BC. Swine influenza: New information on an old problem. *Proc AASP Annual Meeting.* 1991; 3–6.
4. Nayak DP, Twiehaus MJ, Kelley GW, Underdahl MS. Immunocytologic and histopathologic development of experimental swine influenza infection in pigs. *Am J Vet Res.* 1965; 26: 1271–1283.
5. Haines DM, Waters EH, Clark EG. Immunohistochemical detection of swine influenza A virus in formalin-fixed and paraffin-embedded tissues. *Can J Vet Res.* 1993; 57: 33–36.
6. Vincent LL, Janke BH, Paul PS, Halbur PG. A monoclonal-antibody-based immunohistochemical method for the detection of swine influenza virus in formalin-fixed, paraffin-embedded tissues. *J Vet Diag Invest.* 1997; 9:191–195.
7. Cottral G, ed. *Manual of Standardized Methods for Veterinary Medicine.* Comstock, Cornell University: Ithaca, New York. 1979; 72–73, 89–90.
8. Swenson SL, Vincent LL, Lute BM, Janke BH, Lechtenberg KF, Landgraf JG, Schmitt BJ, Kinker DR, McMillen JK. A comparison of diagnostic assays for the detection of swine influenza virus from nasal swabs and lungs. *Proc AASP Annual Meeting.* 1997.

